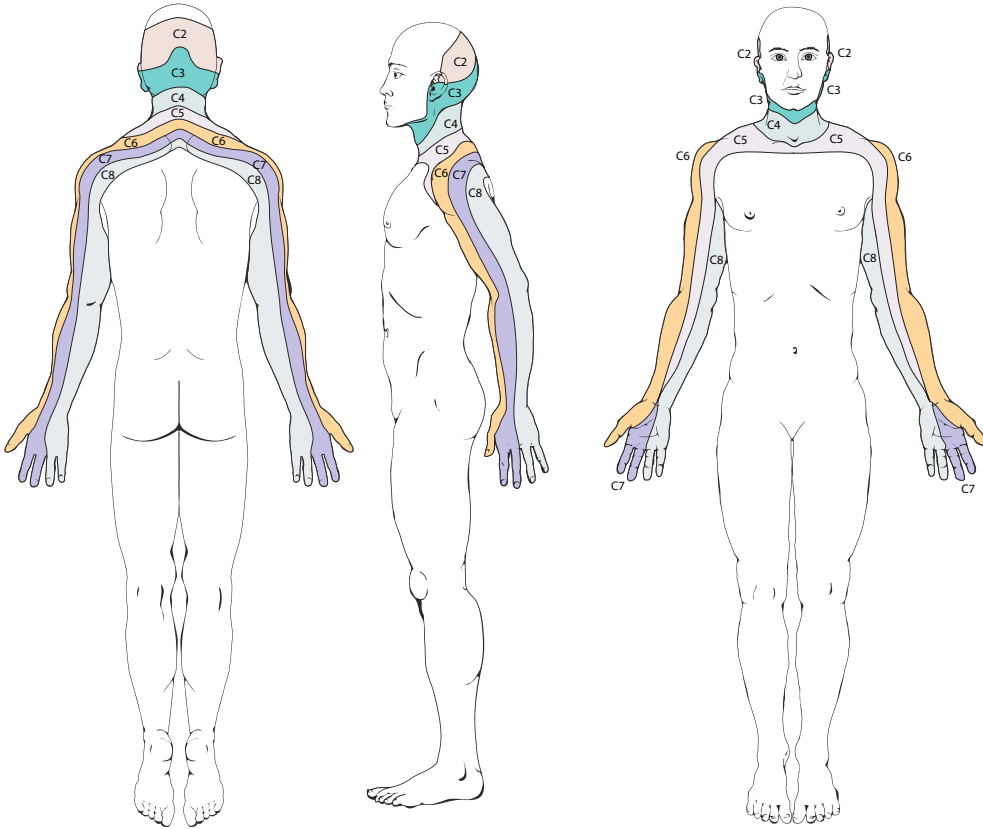
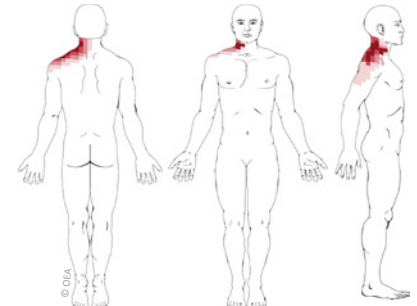


Cervical Radicular Pain Patterns

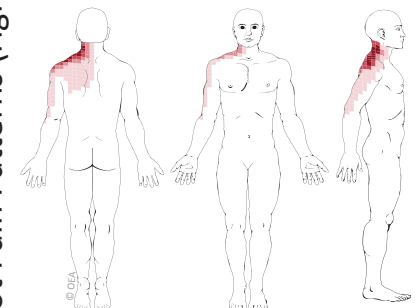


Cervical Dermatomes: Nerve Root Numbness Patterns (above)

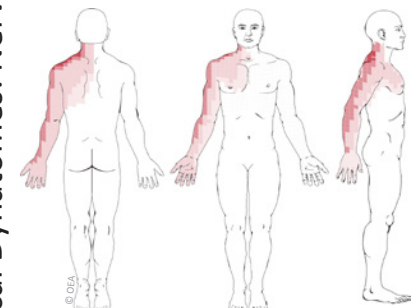
Based on: Slipman CW et al. Symptom provocation of fluoroscopically guided cervical nerve root stimulation. Are dynatomal maps identical to dermatomal maps? *Spine*. 1998;23:2235-42.



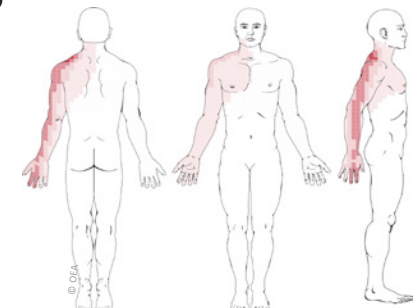
C4 Nerve Root Pain Pattern



C5 Nerve Root Pain Pattern

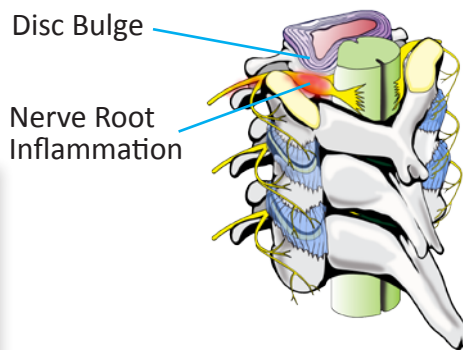


C6 Nerve Root Pain Pattern



C7 Nerve Root Pain Pattern

Cervical Dynatomes: Nerve Root Pain Patterns (right)



RSM
Medical Associates
Renée S. Melfi, MD
 Physical Medicine and Rehabilitation
 Spinal Diagnostics and Interventions
 Musculoskeletal Medicine
 Phone: (315) 701-4000 Fax: (315) 701-4093